



Isolated Left Ventricular Noncompaction Mimicking Cystic Mass

Kistik Kitleyi Taklit Eden İzole Sol Ventriküler Nonkompaksiyon

Isolated Left Ventricular Noncompaction

Barış Buğan¹, Erkan Yıldırım², Uygur Çağdaş Yüksel², Ugur Bozlar³, Turgay Çelik²

¹Malatya Military Hospital, Cardiology Service, Malatya, ²Gulhane Military Medical Academy, Department of Cardiology, Ankara,

³Gulhane Military Medical Academy, Department of Radiology, Ankara, Turkey

Özet

Ventriküler miyokardın nonkompaksiyonu "noncompaction", endokard ve miyokardın normal embriyolojik gelişiminin durması ile oluştuğu düşünülen, yakınlarda tanımlanmış genetik bir kardiyomyopatidir. Tanı, genellikle ekokardiyografi ile konulur. Burada, kistik kitleyi taklit eden izole sol ventriküler nonkompaksiyonlu 29 yaşında erkek bir vakayı sunuyoruz.

Anahtar Kelimeler

Kardiyomyopati; Kistik Kitle; Ekokardiyografi; Manyetik Rezonans Görüntüleme

Abstract

Noncompaction of the ventricular myocardium is a recently recognized genetic cardiomyopathy thought to be caused by arrest of normal embryogenesis of the endocardium and myocardium. The diagnosis is usually made by echocardiography. Herein we report the case of a 29-year-old male with isolated left ventricular noncompaction mimicking cystic mass.

Keywords

Cardiomyopathy; Cystic Mass; Echocardiography; Magnetic Resonance Imaging

DOI: 10.4328/JCAM.1297

Received: 16.09.2012 Accepted: 27.10.2012 Printed: 01.01.2016

J Clin Anal Med 2016;7(1): 120-2

Corresponding Author: Barış Buğan, Malatya Military Hospital, Cardiology Service, 44100, Malatya, Turkey.

T.: +905323476096 F.: +90 4223362043 E-Mail: bbugan@hotmail.com

Introduction

Noncompaction of the ventricular myocardium is a congenital cardiomyopathy characterized by deep intertrabecular recesses connected to the ventricular cavity thought to be caused by arrest of normal embryogenesis of the endocardium and myocardium [1, 2]. It may be isolated or associated with other congenital cardiac defects [2, 3]. Echocardiography is the diagnostic procedure, but the diagnosis is often missed or delayed because of poor echo window in assessment of the LV apex, lack of knowledge about this uncommon disease, and its similarity to other diseases of the myocardium and endocardium [1, 2, 4].

Case Report

A 29-year-old male with history of atypical chest pain was referred to our clinic. During his evaluation, intracardiac mass was discovered on a routine echocardiogram. There were no other symptoms of heart failure or coronary artery disease. Patient has no family history of heart disease or sudden death. On admission, his blood pressure was 125/75 mmHg and the heart rate was 68 beats/min. The 12-lead electrocardiography (ECG) showed normal sinus rhythm. Transthoracic echocardiogram and cardiac magnetic resonance imaging (MRI) were performed. Echocardiogram revealed a prominent cystic mass in the apical interventricular septum with normal left ventricular function (LVEF: 60%), and Color Doppler showed no flow within the cystic mass (Figure 1). MRI showed a typical pattern of noncompacted myocardium predominantly of the left ventricle (LV). Ratio of noncompacted to compacted area was 2.7 (pathological >2) (Figure 2). The LV was mildly dilated with preserved systolic function (LVEF: 50%). The ambulatory ECG documented sinus rhythm. There were no atrial fibrillation and ventricular arrhythmias.

Lacking indications for more aggressive therapy, chronic anticoagulation with warfarin was prescribed. The patient was considered for regular follow-up to include assessment of exercise tolerance, measurement of ventricular size and function, and use of continuous ambulatory ECG. First degree relatives were screened with echocardiography.

Discussion

Noncompaction of the ventricular myocardium is a recently recognized genetic cardiomyopathy. Both familial and sporadic forms of isolated left ventricular noncompaction (ILVN) have been described [2, 3]. The median age at diagnosis was 7 years (ranging from 11 months to 22 years) in the first case series of ILVN [2]. But subsequent case reports have described ILVN in adults such as our patient. Men appear to be affected more often than women. The prevalence was 0.014% of patients referred to the echocardiography laboratory, but the true prevalence is unclear [2, 3].

Clinical manifestations may range from being asymptomatic to presenting with heart failure, malignant arrhythmias, sudden cardiac death, or systemic thromboembolism [1, 2]. Echocardiography is the method of choice in establishing the diagnosis of ILVN. The echocardiographic characteristics of ventricular noncompaction include, segmental thickening of the LV myocardial wall consisting of 2 layers: a thin, compacted epicardial layer and an extremely thick layer with prominent trabecula-

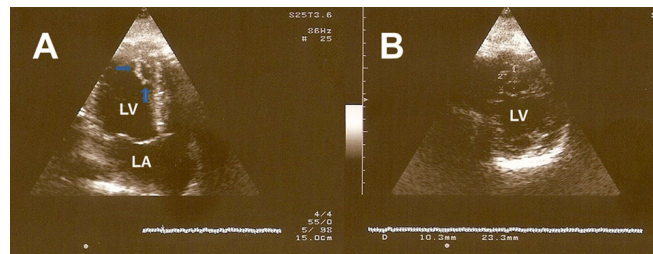


Figure 1. Apical four chambers (A) and parasternal short axis (B) echocardiograms showing a prominent cystic mass (arrows) in the apical interventricular septum.

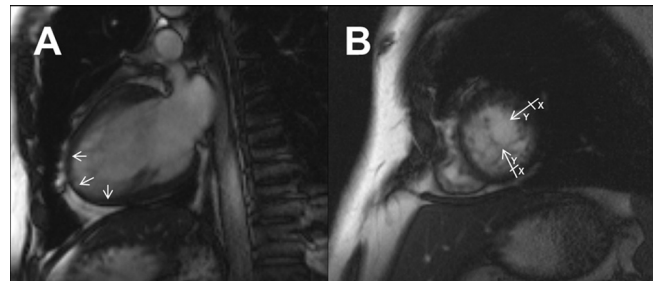


Figure 2. Two chamber (A) and short axis (B) steady state free precession (SSFP) MR images showing a typical pattern of noncompacted myocardium predominantly of the left ventricle. Ratio of noncompacted (Y) to compacted (X) area was 2.7.

tions and deep recesses. Color Doppler imaging demonstrates blood flow through these deep recesses in continuity with the ventricular cavity [1, 2, 5]. However, echocardiography depends on the experience and knowledge of the investigator and has poor echo window in assessment of the LV apex, which is the most commonly noncompacted area [2, 5]. MRI is especially useful when the myocardial involvement is subtle, and better distinguishes the compacted and non-compacted myocardial layers than echocardiography [4]. In our patient, echocardiography revealed a cystic mass (Figure 1) in the interventricular septum, but the MRI showed a typical pattern of noncompacted myocardium (Figure 2).

Treatment for ILVN focuses on the following clinical manifestations: Heart failure, arrhythmias, and systemic embolic events [1-3]. Standard medical therapy for systolic and diastolic ventricular dysfunction is warranted. Because of significant risk of ventricular tachycardia, sudden cardiac death and systemic embolism with atrial fibrillation, ambulatory ECG monitoring should be performed for assessment of arrhythmias [2]. Prevention of embolic complications is also an important management target, and long-term prophylactic anticoagulation for all patients with ILVN has been recommended whether or not thrombus has been found. Screening echocardiography of first degree relatives is recommended, as the familial forms was described with non-compaction [1, 2].

Although echocardiography is the diagnostic method of ILVN, this case highlights the diagnostic benefits of MRI over echocardiography. MRI more clearly visualizes cardiac tissue with trabeculation and has the advantage of good spatial resolution at the apex and lateral wall of the left ventricle. In conclusion, echocardiography should be the first diagnostic procedure, but MRI should be kept in mind for the subtle and suspicious cases. This has significant clinical implications for especially asymptomatic patients to prevent complications of noncompaction including heart failure, thromboembolism, ventricular arrhythmia, and sudden cardiac death.

Competing interests

The authors declare that they have no competing interests.

References

1. Varnava AM. Isolated left ventricular non-compaction: a distinct cardiomyopathy? *Heart*. 2001;86(6):599-600.
2. Weiford BC, Subbarao VD, Mulhern KM. Noncompaction of the ventricular myocardium. *Circulation*. 2004;109(24):2965-71.
3. Oechslin EN, Attenhofer Jost CH, Rojas JR, Kaufmann PA, Jenni R. Long-term follow-up of 34 adults with isolated left ventricular noncompaction: a distinct cardiomyopathy with poor prognosis. *J Am Coll Cardiol*. 2000;36(2):493-500.
4. Alhabshan F, Smallhorn JF, Golding F, Musewe N, Freedom RM, Yoo SJ. Extent of myocardial non-compaction: comparison between MRI and echocardiographic evaluation. *Pediatr Radiol*. 2005;35(11):1147-51.
5. Kohli SK, Pantazis AA, Shah JS, Adeyemi B, Jackson G, McKenna WJ, et al. Diagnosis of left-ventricular non-compaction in patients with left-ventricular systolic dysfunction: time for a reappraisal of diagnostic criteria? *Eur Heart J*. 2008;29(1):89-95.

How to cite this article:

Buğan B, Yıldırım E, Yüksel UÇ, Bozlar U, Çelik T. Isolated Left Ventricular Noncompaction Mimicking Cystic Mass. *J Clin Anal Med* 2016;7(1): 120-2.